Knee Taping - Support / Pain Relief

Indications - injury/laxity - medial collateral ligament of the knee (MCL) or ACL
improve valgus knee alignment
increase proprioceptive feedback
Anterior knee pain
Lateral knee pain
Patellar tendonitis

Equipment:
1) Adhesive spray
2) Bandage Scissors
3) EAB - 7.5cm/2.5cm
4) Rigid P-tape - 3.8cm
5) Protective dressings/pads
6) Molefoam padding 5mm
7) Hypafix - 10cm/5cm
8) Lubrication
9) Hair clippers/Razor

Relevant Anatomy:







Joint position:
Patient in standing resting their hips back onto a raised plinth.
For MCL - knee in slight (10°-20°) flexion.
For ACL - knee in 30-40° flexion with tibia in neutral or slight internal rotation
For Patellar tendon - knee in slight flexion.
Knee needs to be in an aligned position with the hip, the centre of the lateral condyle of the knee and the talus plotting along the same vertical axis.

Requirements/Cautions:
Hairy legs will need to be shaved (if wet shaved then 24 hours prior to tape application) to facilitate proper tape adhesion. Skin needs to be moisturiser-free too. Underwrap is inappropriate here. It is advisable for the athlete to warm-up (eg. ex bike 5mins) prior to taping as there can be considerable increase in thigh and calf dimensions on exertion. If tape is applied to a cold athlete there is a greater risk of restricted circulation, discomfort for the athlete and early fatigue within the constricted muscles.

Technique - MCL weave (P-tape 3.8cm tape + EAB 7.5cm)

- Protective dressings + lubrication applied to distal hamstring tendons and proximal gastrocnemius tendons if required.
- Adhesive spray area to be taped.
- Anchor (1) - 1/3 up the thigh from anterior mid-quad going medially to posterior mid-hamstring.
- Anchor (2) - 1/3 down the lower leg from anterior mid-shin (ensure below the tibial tuberosity) going medially to posterior mid-gastrocnemius.

Tip - both of these anchors can be circumferential around the whole limb if needed but ensure the patient has warmed up. The patient will still need to shave the joint as this will not keep the anchors on a hairy leg.

- First strip goes from anterior anchor (1) obliquely infero-posteriorly crossing over the VMO, the joint line and attaches to the posterior surface of anchor (2). No extra tension needs to be added and do not block the sliding movement of the patella.
- Second strip goes from postero-medial anchor (1) obliquely infer-anteriorly aiming to cross the 1st strip at the joint line and attaching to the anterior surface of anchor (2).
- Repeat this process working backwards overlapping the previous strips by 2/3 to a 1/2. Do not apply anymore strips once you are next to the semimembranosus/semitendinosus tendons (see pics)
- 2-3 further strips can then be added going vertically over the joint line crossing points already applied
- Anchor (1) is then reinforced by 2 anchors, the first half overlaps the bottom 1/2 of the base anchor and the second overlaps the top half.
- Same process on Anchor (2).
- EAB 7.5cm strips - applied on 10% stretch. Apply the first 2-3cms with no tension over the anterior anchor (1), then apply tension whilst laying over the joint line and fix the last 2-3cms with no tension to the posterior anchor (2). Repeat going from the posterior anchor (1) to the anterior anchor (2). The 3rd strip goes vertically from mid-anchor (1) to mid-anchor (2).
- Apply EAB to the calf at the medial side, come around once then move up 1/2 overlapping then finish on the medial edge of the calf. Secure with a P-tape loop. Repeat the same process on the lower thigh (see pics)





Technique - ACL support (P-tape 3.8cm tape + EAB 7.5cm)

- Adhesive spray area to be taped and Hypafix.
- Anchor (1) - 1/3 up the posterior thigh coming 2/3 round
- Anchor (2) - over the tibial tuberosity going halfway round
- Oblique strips are interwoven - start at the tibial tuberosity - no tension first 4cm then tension until the tearing to fix to the anchor. Pull equally in each direction
- Repeat 2-3 pairs of strips overlapping previous by 1/2-1/3.
- Reapply anchors
- 7.5cm EAB strips over each side with a complete loop around the quad (ensure it is contracted) and around the lower limb. Lock off with complete loop of P-tape.





Technique - Superior Tib-Fib P-A glide (P-tape 3.8cm tape)

If patients lateral knee pain reduces in their functional position with a forward glide to the superior tib-fib joint then this technique is indicated.

- Adhesive spray area to be tape.
- Apply Hypafix 5cm - from 4cm behind the fibula around the front to the posterior medial gastrocnemius.
- Apply the P-A glide to the proximal fibula and lay down the tape under tension until past the shin then apply to skin.
- Repeat the same again
- Retest their aggravating exercise
- Wrap with 5cm EAB/Cohesive for durability.



Technique - Patellar tendon compression (EAB 2.5cm)

Positive signs of patellar tendinitis on testing which improves with compression and retest

- Pre-tape spray.
- Cut 2 thin strips of molefoam 5mm padding and stick them together leaving a sticky side free.
- Apply the padding transversely over the patellar tendon.
- Lock the pads in place with EAB 2.5cm - applying 10% stretch only across the front half of the 2 complete loops.
- Lock off with 1 or 2 strips of strappal

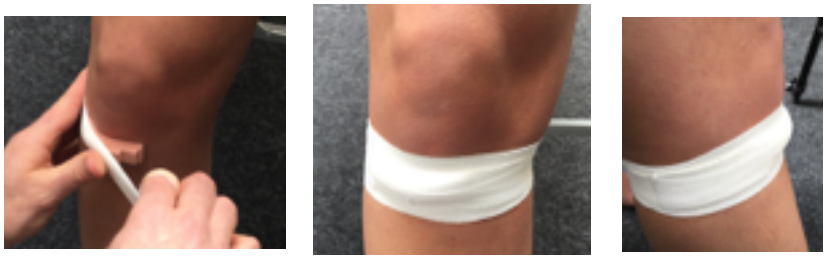

Technique - Tibial Torsion offload (P-tape 3.8cm)
Reduced anterior knee, patello-femoral pain with internal rotation MWM to posterolateral tibia.

- Pre-tape spray.
- Apply 10cm/5cm width Hypafix from 8cm posterior to the sup tib-fib joint and along the tape pathway
- Apply P-tape under no tension for the first 4cm then apply tension whilst performing an Internal rotation of the tibia. Release the tension once the tape has been laid down passed the joint line.
- Repeat the same again

Note - for all techniques check patient comfort in weight bearing and check circulation after the taping is completed. Educate the patient on compromised circulation signs.

Removal - tape removal is easiest when the patient is still perspiring from exercise. If the skin and tape is allowed to dry out again then the tension of the tape can change and blistering can be caused. Easiest removal technique is to use the bandage scissors dipped into petroleum jelly. Go down the recess posterior to the Vastus Lateralis to cut the upper anchors. Continue down to the bottom anchor just anterior to the superior tib/fib joint. Peel the whole taping application off from top to bottom to minimise skin irritation. Use tape remover (alcohol wipes or Isopropanol spray) to lift any adhesive residue. Check the skin for any undue reaction.