Ankle Taping - Support / Pain Relief

Indications - injury/laxity - lateral ligament complex of ankle (ATFL, CFL, PTFL)
calcaneus control
mid-foot supination/pronation control
High ankle sprain - syndesmosis involvement
Pain with Dorsiflexion

Equipment:
1) Underwrap/Cohesive wrap (optional)
2) Adhesive spray (optional)
3) Bandage Scissors
4) Elastic Adhesive Bandage (EAB) - 5cm or 7.5cm
5) Rigid tape - 3.8cm
6) Protective dressings/pads
7) Hypafix
8) Lubrication

Relevant Anatomy:







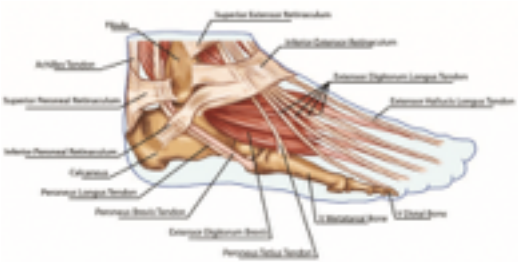



Joint position:
Ankle needs to be maintained in a neutral position (0°) and with no supination/pronation or inversion/eversion.

Variations:
Underwrap can be used but adhesive spray will need to be applied underneath it. This will however add to the overall bulk of the strapping and may mean that footwear fitment becomes a problem for the patient. (See section on underwrap for research evidence).

Technique - Stirrups (3.8cm P-tape) - controls calcaneus inv/ev
- Protective dressings + lube - Flexor retinaculum (sheath protection) + Achilles Tendon (paratenon protection).
- Anchor (1) - Obliquely angled 1/3 up the lower leg - no tension.
- Apply 2-3 stirrup strips starting with the most posterior strip first - going from medial to lateral side.

- Overlap the next strip by 1/2 to 2/3. Depending on the size of the ankle 2-3 strips may be required.

If this is the final rigid technique then:

- Apply 1-2 obliquely orientated anchors.



<u>Technique - Figure 6 (3.8cm P-tape) - controls midfoot sup/pron</u>

Can be used in combination with stirrups or on its own and can be used on either/both sides of the joint depending on requirements.

- Anchor (1) - Obliquely angled 1/3 up the lower leg - no tension.
- Apply 2-3 fig 6 strips with the most posterior strip first. These will start more anterior to the stirrup strips.
- Ensure the patient does not change their foot position whilst applying these sections as it will alter the effectiveness of the technique.

If this is the final rigid technique then:

- Apply 1-2 obliquely orientated anchor.

<u>Caution</u> - ensure the tape does not dig in to the peroneus longus/brevis tendons and the abductor digiti minimi muscle bulk. Pressure here will be uncomfortable for the patient. Try to lay the tape in line with the tissue contours and don't apply pressure to the tape. The support comes from taping the ankle in neutral not from applying pressure to this tape.



Technique - Heel Locks (3.8cm P-tape) reinforces previous 2

Can be used on top of stirrups and fig 6 techniques. Provides anteroposterior stabilisation of the navicular and cuboid. Can help to limit anterior impingement of the talocrural joint.

- Anchor (1) - Obliquely angled 1/3 up the lower leg - no tension.
- Begin the medial side strip placed 50/50 over the tarsonavicular joint and then angled obliquely towards the heel then pass around the lateral calcaneus. The tape then crosses over the achilles to finish on the anterior anchor.
- Begin the lateral side strip placed 50/50 over the calcaneocuboid joint and then angle the tape obliquely towards the heel then pass around the medial calcaneus. The tape then crosses the achilles to finish on the anterior anchor.
- Apply 1-2-obliquely orientated anchors.



Technique - Figure 8 Wrap (EAB or Cohesive 7.5cm):
Used as the finishing technique for any of the above. Offers even compression to the tape and tissues. Provides some elasticity to the techniques thus improving durability and preventing the rigid tape from being torn when stressed. Can be used individually in an acutely swollen ankle to reduce swelling and to secure a compression "horseshoe" in place. Aim to apply an even 10% stretch to the tape during application.

- Begin on top of the midfoot - go medially under the medial arch and straight across up over the lateral border to overlap the start position.
- Now angle obliquely toward the rearfoot come up around the lateral calcaneus going diagonally upwards over the achilles.
- Angle the tape to wrap around the distal tib/fib joints just proximal to the malleoli then angle downwards to cross back over the achilles and track around the medial calcaneus under the rearfoot then up over the ATFL/anterior joint line
- Angle diagonally towards the heel and come diagonally up the other side then track back toward the lower ankle to finish
- Lock off the tape ends with rigid tape



Note - for all techniques check patient comfort in weight bearing and check circulation after the taping is completed. Educate the patient on compromised circulation signs (capillary refill)

Removal - Go down the natural gutter between the medial Achilles and the Soleus and then work under the medial malleolus. Lifting the tape away from the skin with the flat end of the scissors as you go. The patient can help by keeping the foot in dorsiflexion and pulling the toes up. Use tape remover (alcohol wipes or Isopropanol spray) to lift any adhesive residue. Check the skin for any undue reaction.

Technique - Syndesmosis (3.8cm P-tape):
Used to limit external rotation of the foot and compress the distal syndesmosis.

- Protective dressings + lube - TA.
- Anchor around lower leg.
- Begin under the medial arch - go obliquely backwards over the achilles and spiral round to the anterior tibia to finish on the anchor.
- Repeat 2-3 times more and slightly offset the angles to increase rotational control.
- Apply 2 stirrups to secure the first strips
- Wrap with EAB/Cohesive 7.5cm to improve durability





Tip - To give maximum

support this technique can be interwoven with the fig. 6 and heel lock techniques above

Technique - Distal Tib-Fib MWM (3.8cm P-tape):
Used to give pain relief if positive result from A-P glide to distal tib-fib joint.

- Hypafix 5cm from anterior to the fibula around the posterior ankle joint to the anteromedial ankle.
- Apply first 3cm of tape with no tension. Apply A-P glide to the fibula and maintain whilst applying the tape.
- Continue the strip round with no tension from the TA onwards. Repeat the same process with a 2nd strip
- Wrap with EAB/Cohesive 5cm to improve durability

